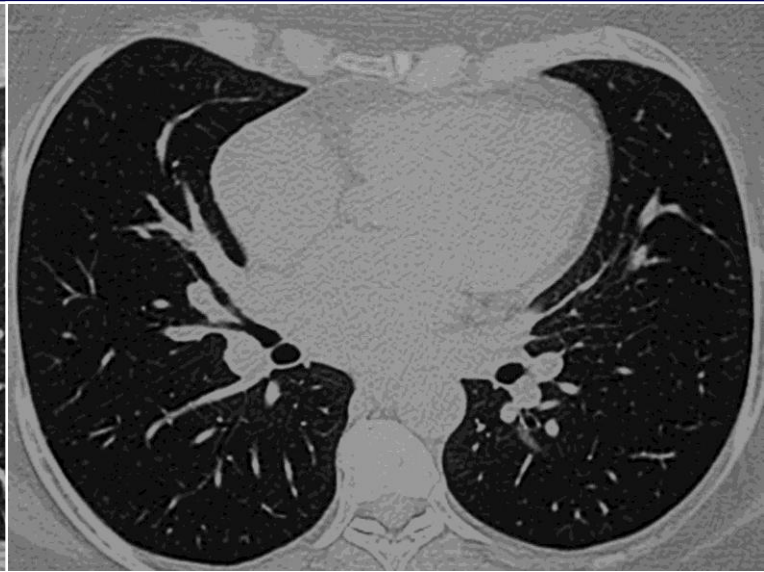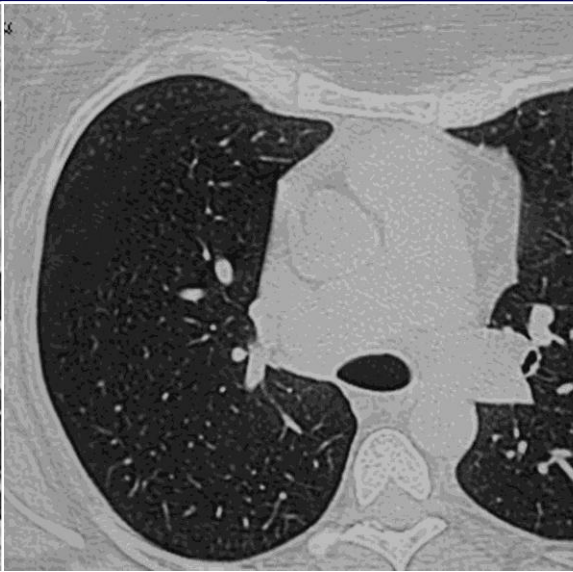
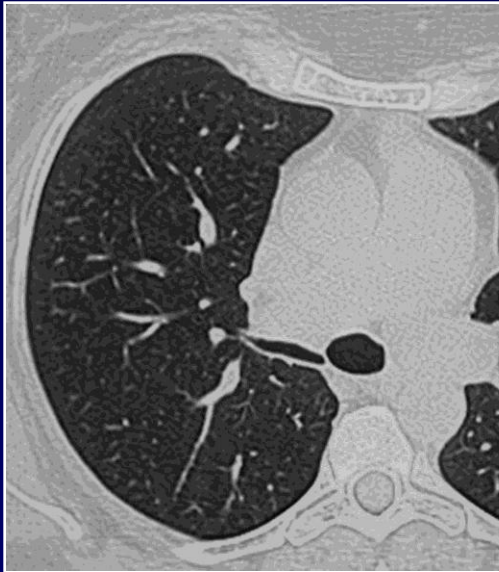
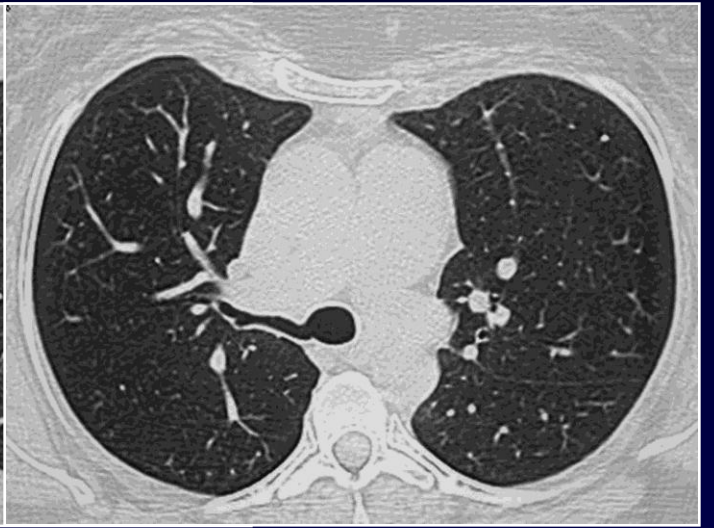
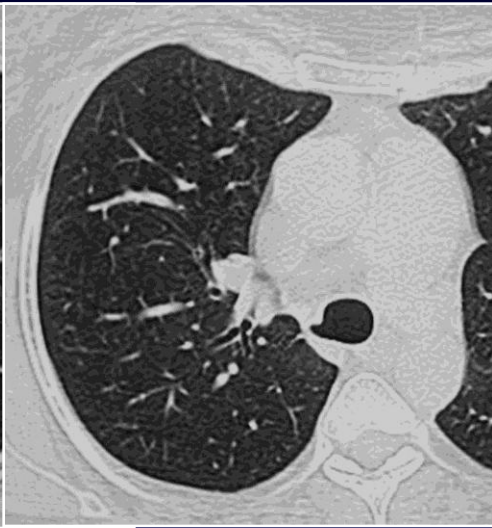

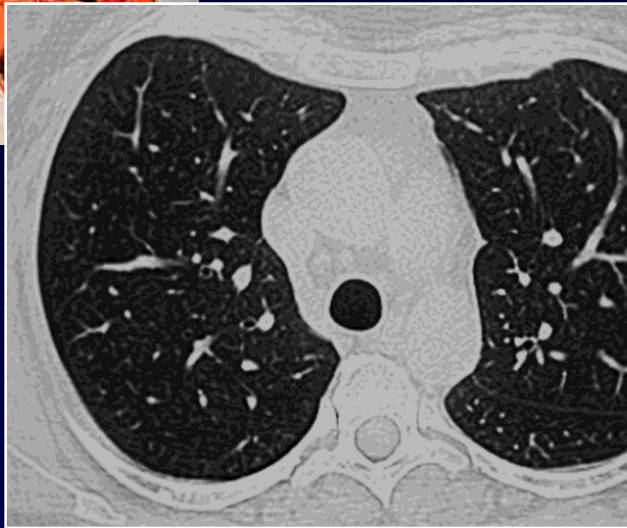
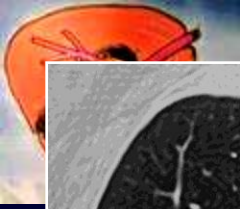

**D. JEANBOURQUIN**

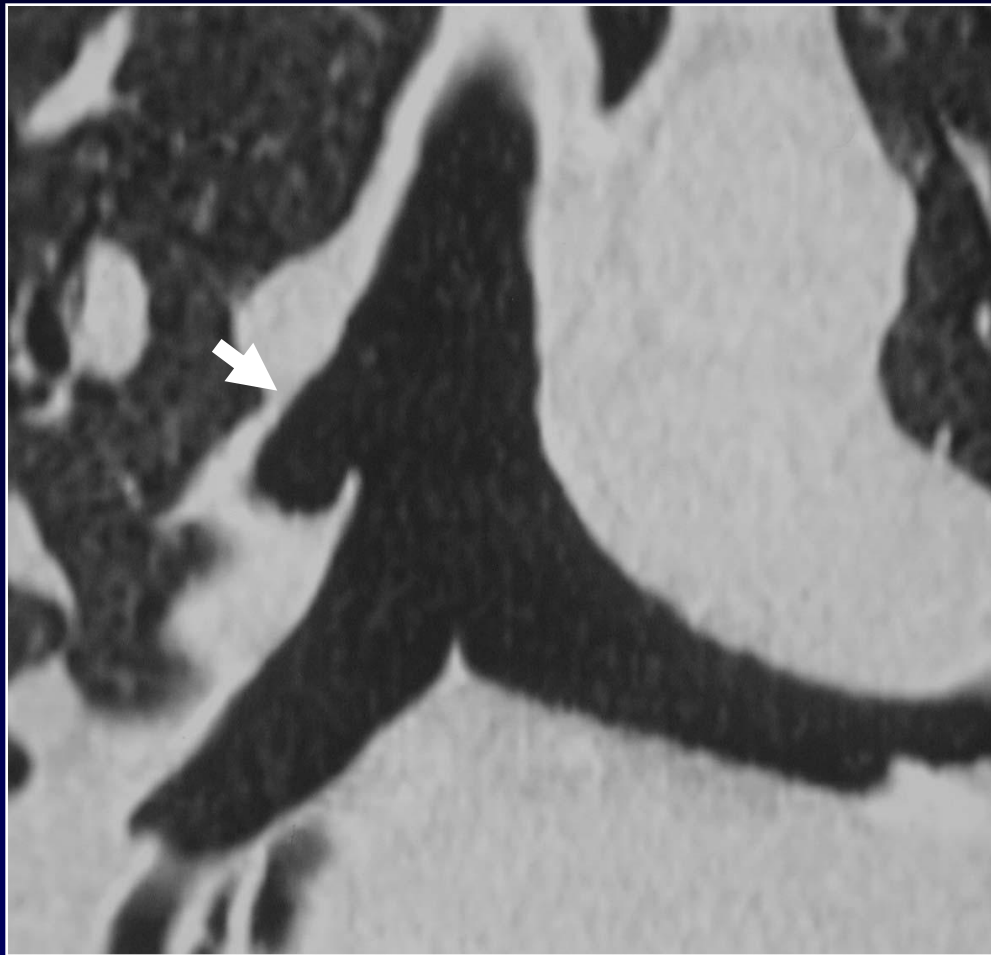
**Femme de 50 ans**

**Découverte fortuite**





**Diagnostic ?**



**Bronche lobaire supérieure droite  
naissant du bord droit de la trachée**